

CASE REPORT

Open Access



Patent ductus venosus and exercise related pulmonary hypertension: a case of a young adult with successful surgery closure

Walter Serra^{1*} , Angelo Placci¹, Cristina Rossi² and Stefano Cecchini³

Abstract: The patent ductus venosus is an embryological portosystemic shunt that connects the umbilical vein to the inferior vena cava and it can be diagnosed incidentally or in subjects suffering from hepatic encephalopathy, hypoxemia or hypoglycaemia. Sometimes it can be found in patients with cardiac defects or hypoxia caused by pulmonary arteriovenous shunting.

Case presentation: A 34-year-old male patient was referred to our medical centre for further evaluation of abdominal pain and moderate exertional dyspnoea. An exercise stress echocardiogram was performed in order to understand the mechanism of the exertional dyspnoea. The test was interrupted due to dyspnoea and desaturation and an estimated pulmonary pressure value of 65 mmHg was detected. Exercise pulmonary hypertension (PH) seems to represent the hemodynamic manifestation of early pulmonary vascular disease, acting as a possible transitional phase anticipating resting PH.

An MRI of the abdomen showed the presence of a portosystemic shunt from a patent ductus venosus, associated with stenosis of the celiac tripod artery. A CT scan, of the pulmonary circulation, showed a normal pulmonary venous return, mediastinal vessel a normal pulmonary artery. Subsequently, taking into consideration the large size (> 25 mm) of the duct, treatment (closure) of the patent ductus venosus with the help of a detachable vascular plug device was not feasible and open surgery rather than a percutaneous invasive approach would be advisable.

Conclusion: Persistent ductus venosus can lead to pulmonary arteriovenous shunt fistula and exercise related pulmonary hypertension. Percutaneous or surgical closure requires detailed planning and an anatomical and physiological evaluations.

Keywords: Patent ductus venosus, Exercise related pulmonary hypertension

Case report

A 34-year-old male patient, height 195 cm tall, and, weighing 99 kg, was admitted to the emergency room of our institution complaining of self-limited epigastric pain with moderate exertional dyspnea.

No history of alcohol abuse or hepatotoxic drug use was declared. There was no family history of hepatic disease. During childhood, he suffered with generalized epilepsy. On clinical examination, the abdomen was prominent

because of hepatomegaly and had a sharp edge and smooth surface. A systolic murmur (2/6) was detected at the second left intercostal space on auscultation of the thorax. ECG showed sinus rhythm with right axis deviation; and an incomplete right bundle branch block. A blood test revealed slightly elevated pancreatic enzymes. The results of a liver function test were normal except for elevated serum ammonia, which raised the suspicion of biliary pancreatitis.

The patient underwent a cholangiography-MRI that ruled out any biliopancreatic diseases but revealed a congenital patent ductus venosus (PDV) associated with suspected stricture of the celiac tripod artery (Fig. 1). Further investigations were then conducted in order to

* Correspondence: wserra@libero.it

¹Cardiology Division, Surgery Department, University Hospital-Parma IT, Via Antonio Gramsci 14, Parma 43100, Italy

Full list of author information is available at the end of the article



© The Author(s). 2020 **Open Access** This article is licensed under a Creative Commons Attribution 4.0 International License, which permits use, sharing, adaptation, distribution and reproduction in any medium or format, as long as you give appropriate credit to the original author(s) and the source, provide a link to the Creative Commons licence, and indicate if changes were made. The images or other third party material in this article are included in the article's Creative Commons licence, unless indicated otherwise in a credit line to the material. If material is not included in the article's Creative Commons licence and your intended use is not permitted by statutory regulation or exceeds the permitted use, you will need to obtain permission directly from the copyright holder. To view a copy of this licence, visit <http://creativecommons.org/licenses/by/4.0/>. The Creative Commons Public Domain Dedication waiver (<http://creativecommons.org/publicdomain/zero/1.0/>) applies to the data made available in this article, unless otherwise stated in a credit line to the data.

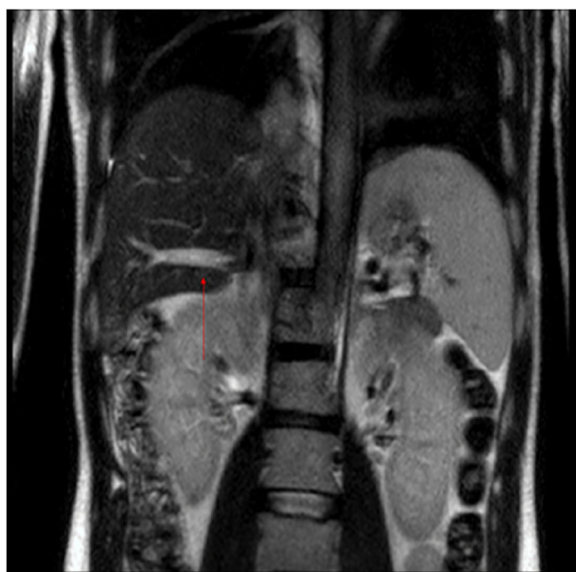


Fig. 1 Cholangiography-MRI that ruled out any bilio-pancreatic diseases but revealed a congenital patent ductus venosus (PDV)

quantify the haemodynamic influence of the vascular anomaly and its relationship to the respiratory symptoms. A Transthoracic echocardiography (TTE) showed a normal left ventricular systolic and diastolic function, no valve dysfunction and mild right ventricular enlargement with normal function at rest (TAPSE 28 mm) (Fig. 2a).

A right atrioventricular gradient of 30 mmHg with dilatation of the right atrial area (21cmq) was found. A Trans-esophageal contrast echocardiogram showed a mild dilatation of the upper left pulmonary vein; intra-cardiac shunts were excluded. To understand the mechanism of the exertional dyspnoea, an exercise stress echocardiogram was performed.

The test was interrupted for dyspnoea and desaturation (SATO2 84%), and an estimated pulmonary pressure value of 65 mmHg was detected. ECG showed a slightly down-sloping ST segment and an incomplete right bundle block (Fig. 2b). The CT scan showed normal pulmonary venous return with no sign of obstruction and a normal pulmonary artery. To investigate a possible gastro-intestinal vascular insufficiency, we decided to perform an abdominal aortography through the right femoral artery as well as, a selective arteriography of the celiac tripod (TC) and the superior mesenteric artery (SMA), (Fig. 3).

Arteriography ruled out any anomaly of the TC or the SMA, and the study of the portal venous return-portal confirmed a porta-cava shunt through a large PDV. In view of the large size (> 25 mm) of the duct, treatment (closure) of the patent ductus venosus, with

the help of a detachable vascular plug, was not felt to be feasible and, after multidisciplinary review, surgical ligation was recommended.

Operating report

After a brief laparoscopic abdominal exploration, the lesser sac was dissected. A vessel loop was used on the hepatic pedicle, the umbilical fossa was exposed, and a PVD was identified and confirmed by intraoperative liver ultrasound. The PDV was completely dissected and encircled with a vessel loop, using the Glissonian approach. A clamping test was performed on the PVD, and intraoperative ultrasound (IOUS) heart monitoring reported no variation of the pulmonary arterial pressure gradient. Similarly, IOUS of the liver ruled out any significant in hepatic blood flow. Then, the PVD was safely divided with a linear vascular stapler (Fig. 4, Video).

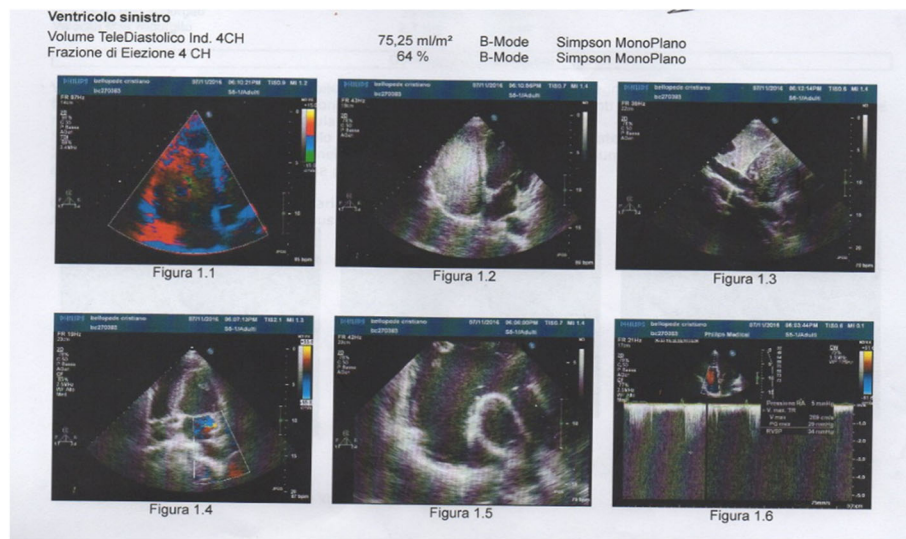
Outcome and follow-up

The patient was admitted to intensive care following the procedure, and the serial liver function tests showed a marked improvement particularly in the ammonia blood level test, which reached a normal range on the fifth postoperative day. The patient was subsequently discharged from the unit with no complications.

A one-month follow-up ultrasound of the abdomen confirmed the persistent closure of the ductus venosus and showed a partial portal thrombosis of the stump of the left portal vein, which was successfully treated with a 3-month oral anticoagulant regimen. Two months after the surgery, an exercise stress echocardiogram was performed, that documented the absence of the development of pulmonary hypertension by exertion with increased watts (125 W) performed and normal oxygen saturation level. At the 6-month follow-up visit, a blood test confirmed normal liver function and serum ammonia levels, even though preoperative repeated abdominal complaints had been reported.

Discussion

The ductus venosus (OMIM 601466) is normally closed 2 weeks after birth. As the pressure of the umbilical vein decreases in the first few minutes of life, functional closure occurs. True obliteration of the ductus venosus is completed in 15–20 days [1–3]. The ductus venosus may remain patent because of increased vascular resistance caused by a poorly developing intrahepatic portal system [4]. The clinical presentation and the symptoms of PVD are controversial as the management and its treatment [5–7]. Some authors have reported a wide variety of

**A**

BP Exercise ECHO

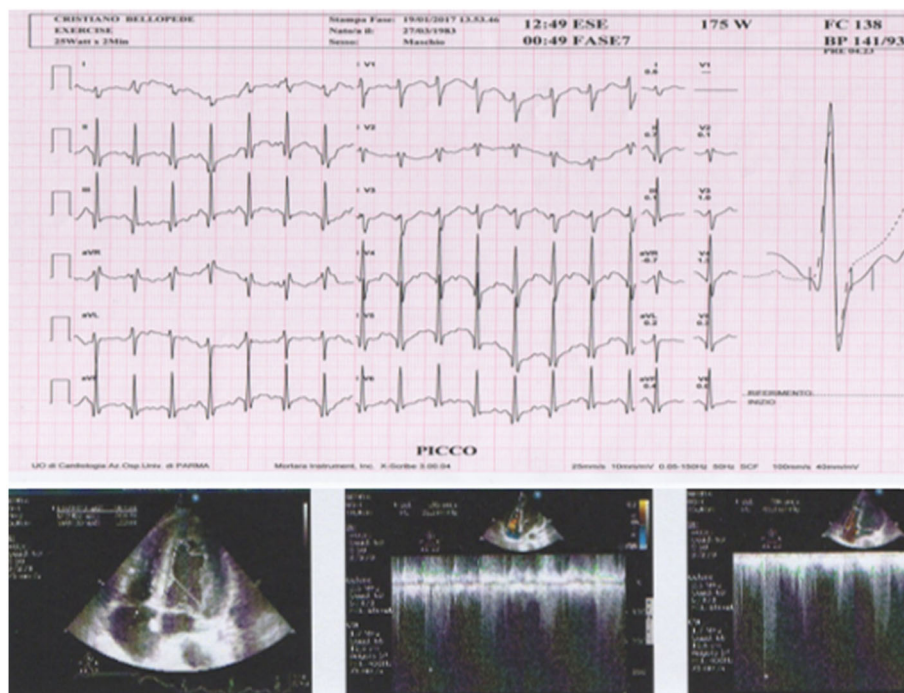
**B**

Fig. 2 a Transthoracic echocardiography (TTE) showed a normal left ventricular systolic and diastolic function, no valve dysfunction, mild right ventricular enlargement with normal function at rest. **b** An echocardiogram was performed by physical exertion. The test was interrupted for dyspnea and desaturation (SATO2 84%) and a value of 65 mm/Hg estimated pulmonary pressure was detected. At the ECG appearance of slightly down sloping ST tract and incomplete right bundle block

symptoms at presentation in patients diagnosed with a congenital portosystemic shunt, including respiratory failure and mild pancreatitis [3]. In our case, the

patient presented with exertional dyspnoea, mild pancreatitis and a chronic portosystemic shunt. An increase in pulmonary pressure after exertion is closely

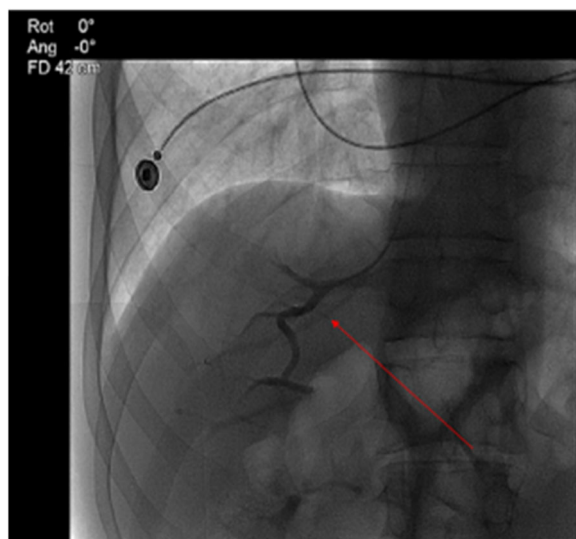


Fig. 3 Abdominal aortography through the right femoral vein and a selective arteriography of the celiac tripod (TC) and the superior mesenteric artery (SMA), in order to investigate on possible gastro-intestinal vascular insufficiency

related to the increase in the flow of the pulmonary circulation due to a portosystemic shunt, better defined as ‘hepatopulmonary syndrome’(HPS).

However there is an increasing awareness of the clinical relevance of an abnormal pulmonary hemodynamic response during exercise. Exercise PH has been defined as the presence of resting mPAP < 25 mmHg and mPAP > 30 mmHg during exercise with total pulmonary

resistance > 3 Wood units, during RHC [8]. Exercise PH seems to represent the hemodynamic manifestation of early pulmonary vascular disease, acting as a possible transitional phase of resting PH.

The variability of the increase of pulmonary artery systolic pressure (PAPs) during exercise is most likely dependent on the variability of the right ventricle function and could be used to evaluate the contractile reserve of the right ventricle. Closure of the shunt should be considered as early as possible, in order to prevent complications such as pulmonary hypertension. Once irreversible lesions of the pulmonary arteries are present, the regression of pulmonary hypertension will not occur. Our results demonstrated that, even if closure/ligation of the PDV is feasible and safe, only the portosystemic shunt has been reversible. The association between PDV and congenital heart disease or pulmonary hypertension must be considered. Ohno [9] and colleagues demonstrated thromboembolic pulmonary arterial hypertension to be a serious complication in the presence of congenital portosystemic venous shunts. Although rarely observed, PDV should be considered as part of the differential diagnosis in young patients presenting with portosystemic shunts without evidence of liver disease. As reported by Jacquemin and colleagues, the shunts between portal branches and hepatic veins can be closed by a percutaneous device, depending on the size and number of communications [9]. A PDV can be successfully managed in this way, except when it is too wide or too short to safely block the device in its lumen, in which case surgery is recommended. In our case, a surgical approach was required due to the large size of the ductus venosus.

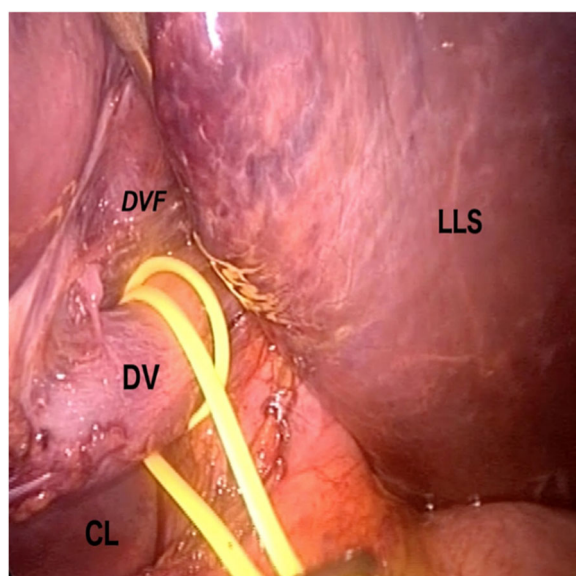


Fig. 4 The PDV was thoroughly dissected free and encircled with a vessel-loop through a glissonian approach

Conclusion

Persistent ductus venosus can lead to pulmonary arterio-venous shunt fistula and exercise related pulmonary hypertension. Percutaneous or surgical closure requires detailed planning as well as anatomical and physiological evaluations.

Before closure or ligation, intraoperative monitoring of pulmonary haemodynamics is recommended.

Supplementary information

Supplementary information accompanies this paper at <https://doi.org/10.1186/s40949-020-00032-0>.

Additional file 1: Video. The PDV was thoroughly dissected free and encircled with a vessel-loop through a glissonian approach. Then the PVD was safely divided with a linear vascular stapler.

Abbreviations

PH: Pulmonary Hypertension; PDV: Patent Ductus Venosus; CT: Computed Tomography; TTE: Transthoracic Echocardiography; TC: Celiac Tripod; SMA: Superior Mesenteric Artery

Acknowledgements

"Not applicable" in this section.

Authors' contributions

WS major contributor in writing the manuscript and prepared the images; AP involved in revising manuscript critically for important intellectual content; WS made substantial contributions to conception and design, interpretation of data and involved in giving final approval of the version to be published. SC performed the surgical procedure and followed the follow-up, CR performed non-invasive and invasive radiological diagnostics. All authors read and approved the final manuscript.

Authors' information

Not applicable.

Funding

I have no funding for this research.

Availability of data and materials

All data generated or analysed during this study are available from the corresponding author or reasonable request.

Ethics approval and consent to participate

Not applicable.

Consent for publication

"Written informed consent was obtained from the patient's legal guardian or next of kin) for publication of this case report and any accompanying images. A copy of the written consent is available for review by the Editor-in-Chief of this journal."

Competing interests

The author is not having any financial interest. There isn't any Conflict of interests.

Author details

¹Cardiology Division, Surgery Department, University Hospital-Parma IT, Via Antonio Gramsci 14, Parma 43100, Italy. ²Radiology Institute University-Hospital-Parma IT, Parma, Italy. ³Surgery Institute University-Hospital Parma IT, Parma, Italy.

Received: 13 November 2018 Accepted: 19 May 2020

Published online: 04 June 2020

References

1. Mitchell IM, Pollock JCG, Gibson AAM. Patent ductus venosus. *Pediatr Cardiol.* 1991;12:181–18.
2. Shen B, Younossi ZM, Dolmatch B, Newman JS, Henderson JM, Ong JP, Gramlich T, Yamani M. Patent ductus venosus in an adult presenting as pulmonary hypertension, right-sided heart failure, and portosystemic encephalopathy. *Am J Med.* 2001;110(8):657–60.
3. Mori H, Hayashi K, Fukuda T, et al. Intrahepatic portosystemic venous shunt: occurrence in patients with and without liver cirrhosis. *AJR.* 1987;149:711–4.
4. Kamata S, Kitayama Y, Usui N, et al. Patent ductus venosus with a hypoplastic intrahepatic portal system presenting intrapulmonary shunt: a case treated with banding of the ductus venosus. *J Pediatr Surg.* 2000;35:655–7.
5. Schwartz YM, Berkowitz D, Lorbert A. Transvenous coil embolization of a patent ductus venosus in a 2-month-old child. *Pediatrics.* 1999;103:1045–7.
6. Marx M, Huber WD, Crone J, et al. Interventional stent implantation in a child with patent ductus venosus and pulmonary hypertension. *Eur J Pediatr.* 2001;160:501–4 encephalopathy. *Am J Med* 2001; 110:657–660.
7. Maeda T, Mori H, Aikawa H, Komatsu E, Kagawa K. Therapeutic embolization of intrahepatic portosystemic shunts by retrograde transcaval catheterization. *Cardiovasc Intervent Radiol.* 1993;16:245–7.
8. Kovacs G, Herve P, Barbera JA, et al. An official European Respiratory Society statement: pulmonary haemodynamics during exercise. *Eur Respir J.* 2017; 50–5.
9. Ohno T, Muneuchi J, Ihara K, Yuge T, Kanaya Y, Yamaki S, Hara T. Pulmonary hypertension in patients with congenital portosystemic venous shunt: a previously unrecognized association. *Pediatrics.* 2008;121(4):e892–9.

Publisher's Note

Springer Nature remains neutral with regard to jurisdictional claims in published maps and institutional affiliations.

Ready to submit your research? Choose BMC and benefit from:

- fast, convenient online submission
- thorough peer review by experienced researchers in your field
- rapid publication on acceptance
- support for research data, including large and complex data types
- gold Open Access which fosters wider collaboration and increased citations
- maximum visibility for your research: over 100M website views per year

At BMC, research is always in progress.

Learn more biomedcentral.com/submissions

